



Annalise Enterprise 3.0

User Guide

English

Annalise Enterprise Product

Product version: **3.0**

Date of issue: **2022-04-21**



Copyright © ANNALISE-AI PTY LTD, 2021

ARTG. No. 343577



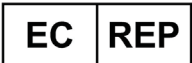ANNALISE-AI PTY LTD

ACN 635 645 260

Level 21, 60 Margaret Street,
Sydney NSW 2000

AUSTRALIA

www.annalise.ai



QualRep Services B.V.
Utrechtseweg 310 - Bldg B42,
NL-6812 AR Arnhem,
THE NETHERLANDS

globalreg@qservegroup.com

New Zealand Sponsor

AA-Med NZ Ltd.
Level 7, 54 Gill Street,
New Plymouth, 4310
NEW ZEALAND

Tel: 0800-440-238

Malaysia Authorised Representative

ARQon Medtech Sdn Bhd
No. 20, Jalan Sasa 4, Taman Gaya, 81800,
Johor
MALAYSIA

info@arqon.com

Registration Number: GA5216421-60402

UK Responsible Person

Qserve Group UK, Ltd. 49 Greek Street
Soho, London W1D 4EG
UNITED KINGDOM

globalreg@qservegroup.com

Indian Voluntary Registration Number

Annali-AUS/I/MD/003060

PRODUCT USE	4
<i>Intended purpose</i>	<i>4</i>
<i>Indications for use</i>	<i>4</i>
<i>Intended user</i>	<i>4</i>
<i>Intended patient population</i>	<i>4</i>
<i>Contraindications</i>	<i>4</i>
<i>Annalise product compatibility</i>	<i>5</i>
<i>Installation and system requirements</i>	<i>5</i>
ABOUT ANNALISE ENTERPRISE	6
<i>Product description</i>	<i>6</i>
<i>Annalise Viewer</i>	<i>6</i>
<i>Worklist Triage</i>	<i>6</i>
<i>Artificial intelligence (AI) algorithm</i>	<i>6</i>
<i>Annalise Viewer functions</i>	<i>7</i>
<i>Security features</i>	<i>18</i>
GETTING STARTED	19
<i>Overview</i>	<i>19</i>
<i>Run Annalise Viewer Adapter</i>	<i>19</i>
<i>Launch Annalise Viewer</i>	<i>19</i>
<i>Access initial functions</i>	<i>20</i>
<i>Set user preferences</i>	<i>22</i>
<i>Add server settings</i>	<i>23</i>
USING THE ANNALISE VIEWER	24
<i>Review AI findings</i>	<i>24</i>
<i>Provide feedback</i>	<i>27</i>
TROUBLESHOOTING	29
<i>Problems and solutions</i>	<i>29</i>
<i>Support and feedback</i>	<i>31</i>
APPENDICES	32
<i>Findings list</i>	<i>32</i>
<i>Annalise CXR ontology tree</i>	<i>32</i>
<i>Annalise CTB ontology tree</i>	<i>43</i>
<i>Symbol glossary</i>	<i>54</i>

Product use

Intended purpose	<p>Annalise Enterprise is a medical device intended to assist clinicians with the interpretation of radiological imaging studies and provide notification of suspected findings.</p>
Indications for use	<p>Annalise Enterprise identifies suspected findings in:</p> <ul style="list-style-type: none"> • digitised (CR) or digital (DX) chest X-ray studies taken in the anterior-posterior (AP) or posterior-anterior (PA) and optionally lateral (LAT) orientations of adult patients • non-contrast brain CT scans (brain kernel) of adult patients <p>For chest X-ray (CXR), the device improves the detection of radiological findings visible on chest X-rays. For CT Brain (CTB), the device supports the detection of radiological findings visible on non-contrast CT brain scans.</p> <p>The device identifies 124 CXR findings and 130 CTB findings (as defined in the Findings list on page 32).</p> <p>The device is used on a PC workstation in conjunction with a medical imaging viewer (i.e. PACS system).</p> <p>The device may also be configured to provide input to worklist software to assist with notification and triaging. The device identifies studies with selected findings and communicates these studies to the worklist software which enables triaging of the worklist and notification.</p> <p><u>Note:</u> Worklist Triage and CTB are additional licenced options and are not available in all regions.</p>
Intended user	<p>The device is intended to be used by trained clinicians who are qualified to interpret chest X-rays and/or CT scans as part of their scope of practice.</p>
Intended patient population	<p>The intended population is:</p> <ul style="list-style-type: none"> • CXR: Patients who are 16 years or older • CTB: Patients who are 18 years or older
Contraindications	<p>The device:</p> <ul style="list-style-type: none"> • is not intended to provide direct diagnosis • can only be used on patients who are 16 years or older (for CXR) or for patients who are 18 years or older (for CTB) • does not enable an increase in the clinician's scope of practice



WARNING

Qualified clinicians who interpret chest X-rays and or brain CT scans as part of their scope of practice hold ultimate responsibility for interpreting studies.

The clinician must review the Annalise Enterprise output concurrently with the original chest X-ray images or brain CT scan and all other relevant clinical information before making their clinical decisions.

Annalise product compatibility

Annalise Enterprise 3.0 is compatible with:

- Annalise Integration Adaptor **2.1** and **2.2**
- Annalise Viewer **2.0** and **2.1**

Installation and system requirements

Refer to the *Annalise Enterprise Administration Guide* for details about system requirements and installation.

About Annalise Enterprise

Product description Annalise Enterprise is a clinical decision support application which uses artificial intelligence (AI) algorithms to assist clinicians with the interpretation of radiological imaging studies. It is compatible with image and order management systems such as picture archiving and communication systems (PACS) and radiological information systems (RIS).

Annalise Enterprise contains the following:

- Annalise Viewer
- Worklist Triage

Note: The availability of CXR, CTB and Worklist Triage features depend on the regulatory requirements in your region.

Annalise Viewer

The Annalise Viewer displays the AI results of adult chest X-ray cases and non-contrast CT brain images (including findings and localisation information).

The viewer includes chest X-ray (CXR) and CT brain (CTB) modules.

Note: CTB is not available in all regions.

Worklist Triage

Annalise Enterprise uses an Artificial Intelligence (AI) algorithm to provide notification of selected findings for worklist prioritisation and triage.

Each organisation can specify the findings that will result in triage and the priority of each finding. The exact functionality available depends on the worklist software used.

If a worklist software vendor does not provide current worklist priority details, Annalise Enterprise will only triage findings with the highest rank. This ensures that it will never decrease a study's existing priority in the worklist.

Note: Worklist Triage is not available in all regions.

Artificial intelligence (AI) algorithm

The Artificial Intelligence (AI) algorithm used in the device is a convolutional neural network trained on over 750,000 imaging studies. It uses deep-learning techniques to:

- highlight the relevant areas of interest for a subset of findings
- display the localisation of clinical findings, and
- identify laterality.

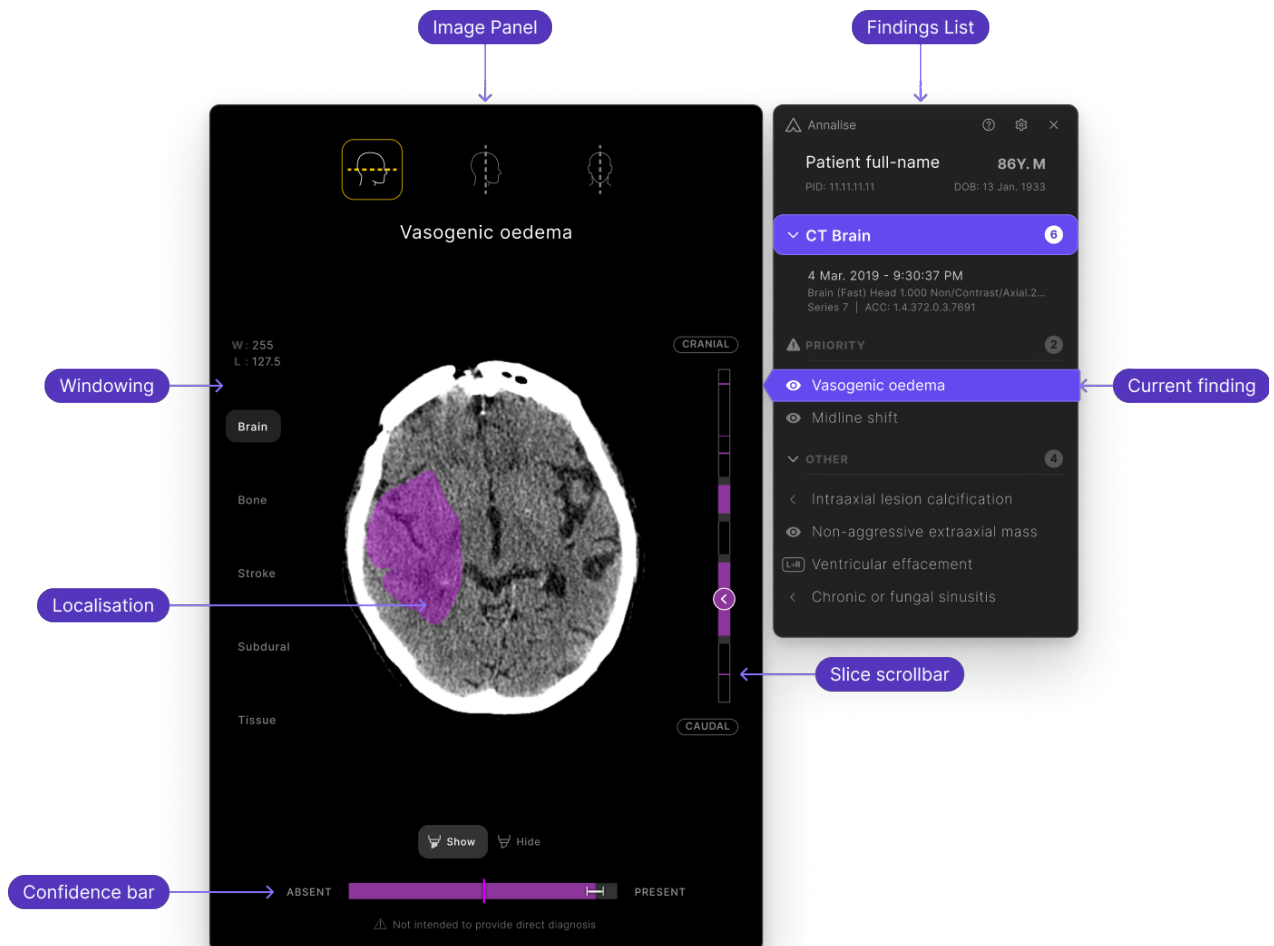
Images used to train the algorithm were sourced from datasets across three continents from a range of manufacturers and different X-ray and CT machines.

Annalise Viewer functions

The following section outlines the functions available on the Annalise Viewer for both chest X-ray (CXR) and CT brain (CTB) studies.

If your organisation has enabled the feedback function, extra functions will display when you are in 'feedback mode'.

Main components

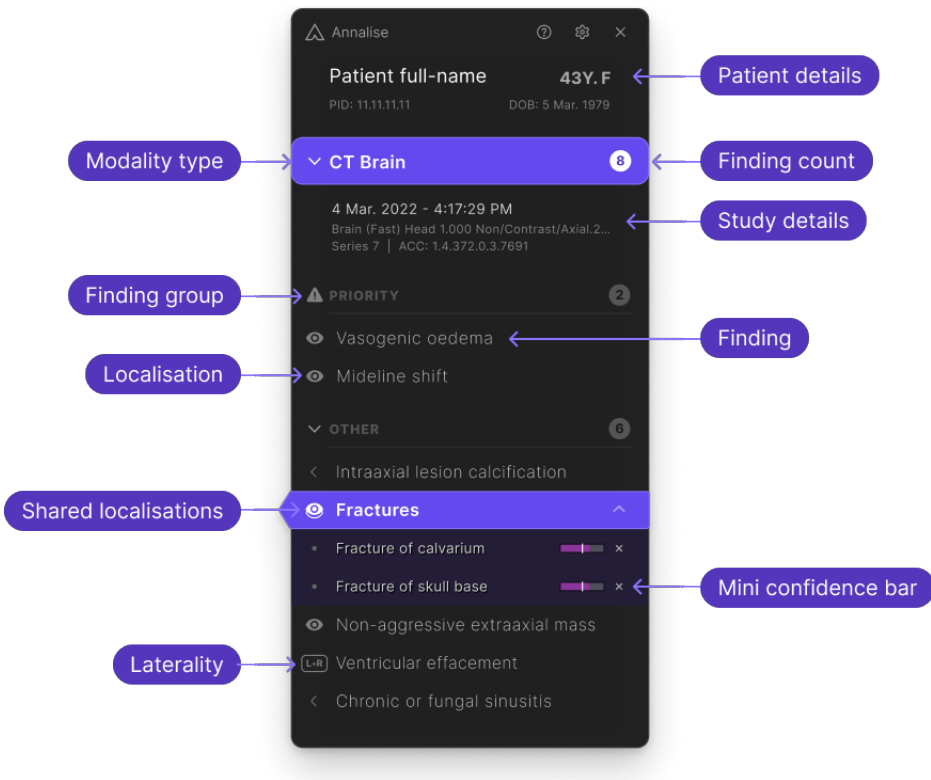


Note: CTB is not available in all regions.

For further details see:

- [Findings List](#) on page 8
- [Study Details Panel \(CXR only\)](#) on page 8
- [Image Panel: CTB](#) on page 9
- [Image Panel: CXR](#) on page 10
- [Feedback mode](#) on page 11

Findings List



Study Details Panel (CXR only)

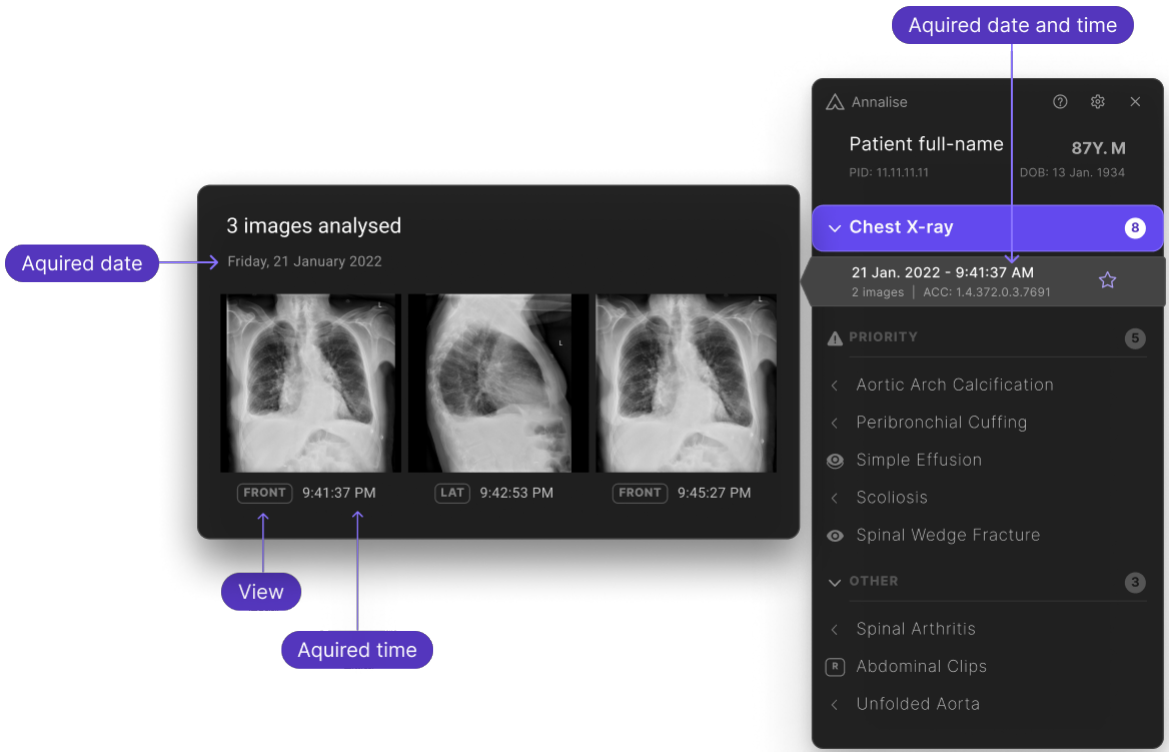
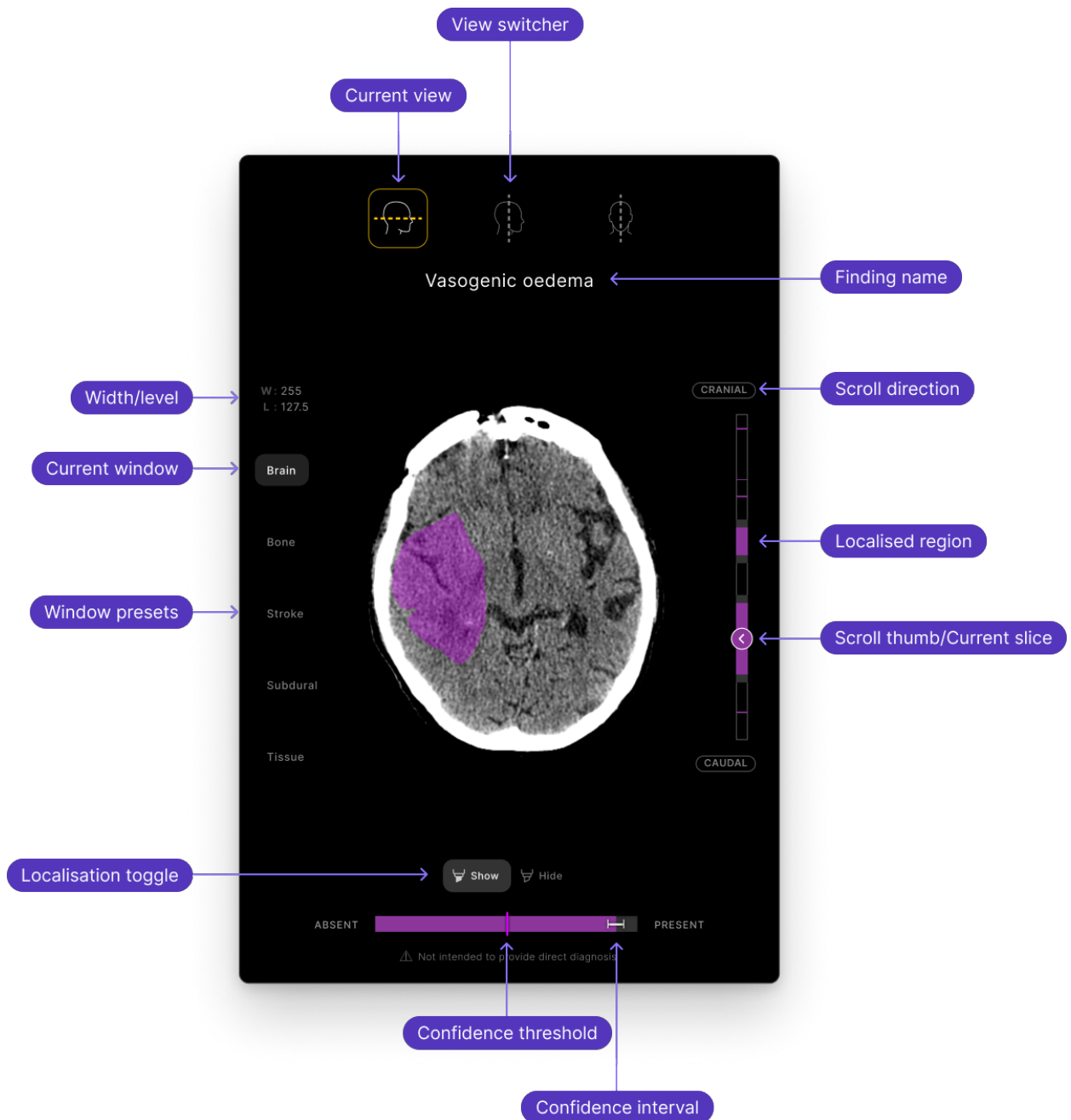
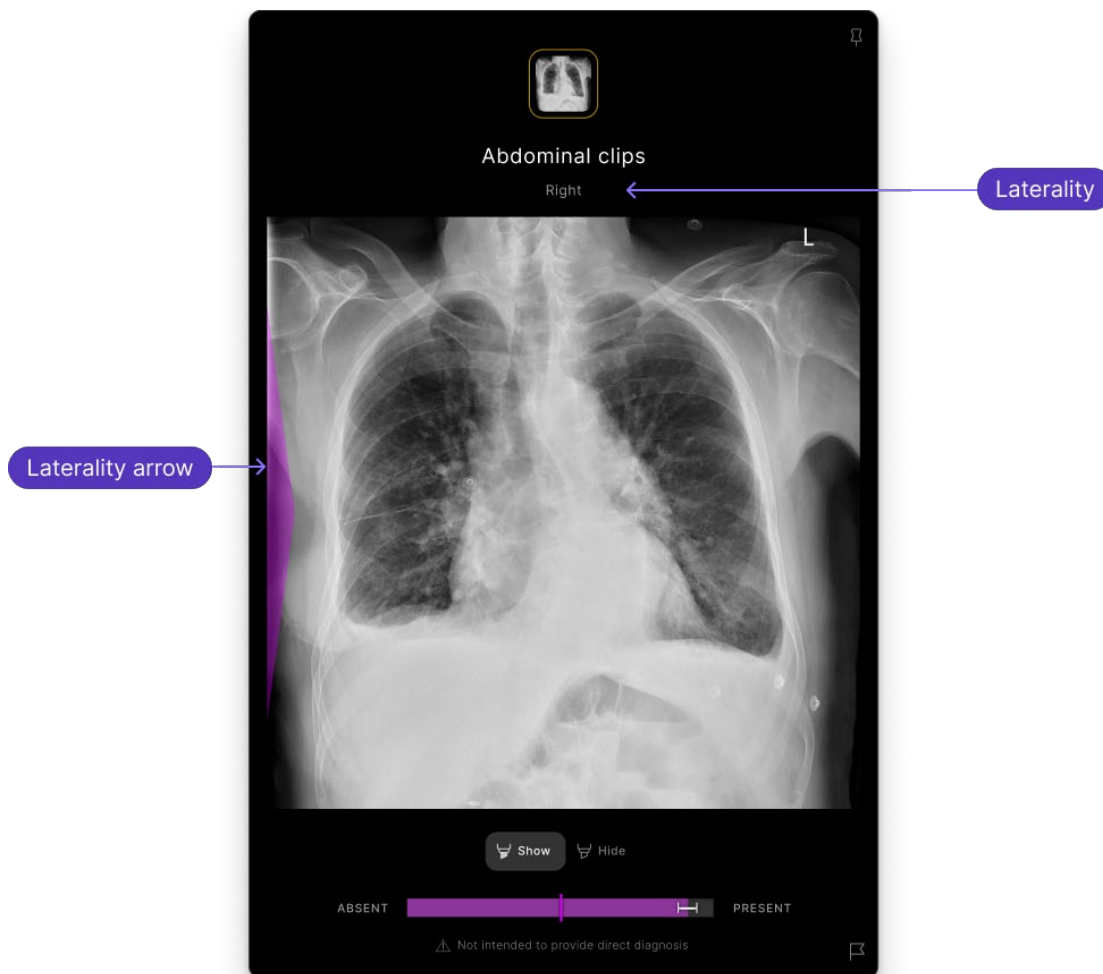


Image Panel: CTB

Note: The CTB module may also display laterality instead of localisation (see *Image Panel: CXR* on page 10).

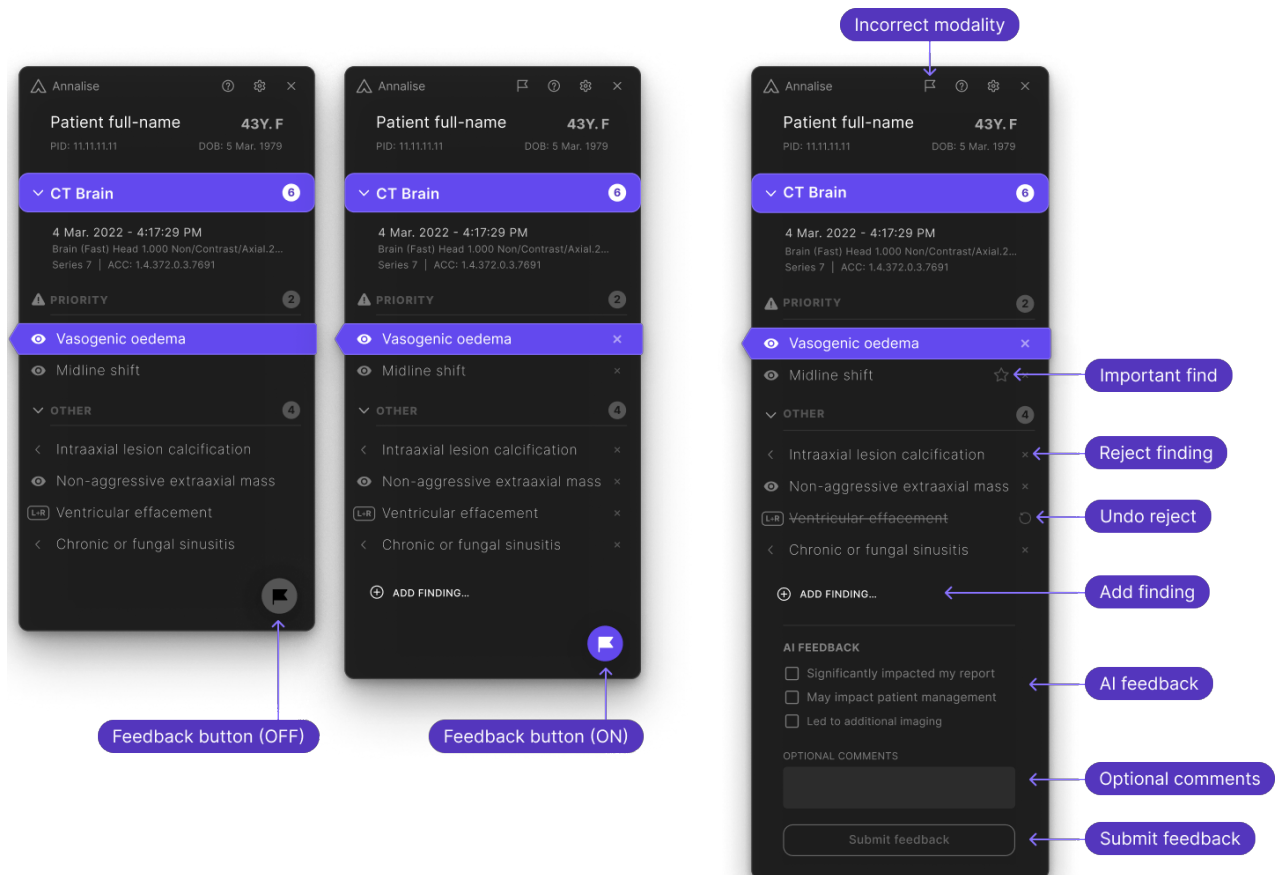
Note: CTB is not available in all regions.

Image Panel: CXR



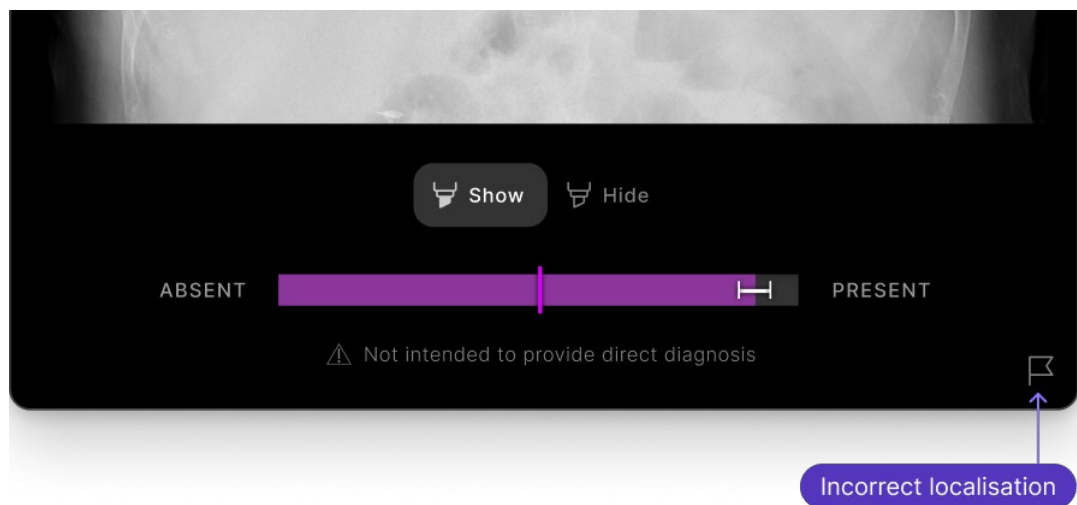
Note: The CXR module may also display localisation instead of laterality (see [Image Panel: CTB](#) on page 9).

Feedback mode: Findings List



Note: If the feedback function has been enabled by your organisation, some or all of these options will display, depending on the type of feedback enabled (see [Feedback mode functions](#) on page 17).

Feedback mode: Image Panel



Findings List

The Findings List is located on the right of the Image Panel.

It displays details about the patient and the modality as well as information about the current study and its associated findings. For CXR studies, it enables you to access other analysed images (see [Study Details Panel \(CXR only\)](#) on page 14).

The Findings List also includes the **Help** and **Settings** functions.

The following functions display on the Findings List:

Function	Details
Patient details	<p>The following patient details display for the current study:</p> <ul style="list-style-type: none"> • Name • Age • Gender • Patient ID (PID) • Date of birth (DOB)
Modality type	<p>The Modality type indicates the current modality (i.e. 'Chest X-ray' or 'CT Brain').</p> <p>It also displays the total number of findings for the current study.</p>
Study details	<p>The Study details display the following:</p> <ul style="list-style-type: none"> • acquisition date and time <i>The date and time the X-ray/CT machine recorded the study.</i> • either: <ul style="list-style-type: none"> - CTB: The series number within the current study and the series description, or - CXR: The number of other analysed images for the study • study description <i>If the description is more than 64 characters, an ellipsis ('...') will display at the end, indicating that there is further information in this field. If this occurs, hover your mouse over the ellipsis to see the full description.</i> • accession number <i>A unique number used to identify a diagnostic report. All images within a study will have the same accession number.</i>
Finding	<p>The suspected radiological findings detected by the AI model.</p> <p>If the model detects that no findings are present, the Annalise Viewer will not contain any results (and the 'No priority findings' message will display).</p>
Finding count	<p>The Finding count that displays beside each finding group indicate the number of findings in that group.</p>

continued

Function	Details
Finding groups	<p>Finding groups are located on the Findings List.</p> <p>All findings are grouped according to status or type. Each finding has both a pre-defined display order and a group to which it belongs.</p> <p>The following groups* display:</p> <ul style="list-style-type: none"> • Priority <i>Findings in this group always display.</i> • Other • User added <i>This group displays if a user adds any additional findings.</i> • Technical <i>This group displays if one or more findings are classified as 'technical' (i.e. non-anatomical artefacts which occurred during the X-ray or scan).</i> <p>*Your organisation can request to configure the following:</p> <ul style="list-style-type: none"> • group names • displaying certain findings only • adding another group, and/or • determining the findings that display within each group. <p><u>Note:</u> As the first group will always contain findings that are more clinically relevant (regardless of whether it is called 'Priority' or has another name), it cannot be collapsed.</p>
Localisation	<p>The Localisation icon displays when localisation is associated with the finding.</p> <p>See Localisation on page 16.</p>
Shared localisations (CTB only)	<p>The Shared localisation icon displays when more than one finding shares the same localisation.</p> <p>These findings are grouped together to make it easier for the radiologist to interpret the study. Each group includes a shared localisation 'title' and the associated findings displayed underneath (each with their own confidence levels – see Mini confidence bar, below).</p> <p>When you click this title, the shared localisation displays on the Image Panel.</p> <p>By default, each shared localisation group will be collapsed. Click the down arrow next to the title to display the associated findings or click the up arrow to collapse them.</p>
Mini confidence bar (CTB only)	<p>The Mini confidence bar indicates the confidence level for a finding.</p> <p>It displays next to the findings that are associated with a shared localisation only.</p>

continued

Function	Details
Laterality	<p>The Laterality icon displays if the finding is localised to left or right.</p> <p>The icon indicates the side (or sides) of the body to which the finding relates:</p> <ul style="list-style-type: none">• L – Left• R – Right• L + R – Bilateral <p>See Laterality on page 16.</p>
Feedback button	<p>The Feedback button enables you to enter feedback mode and provide feedback about the AI model's performance.</p> <p><u>Note:</u> This button only displays if the feedback function has been enabled for your organisation.</p>

Study Details Panel (CXR only)

The Study Panel displays for CXR studies only. It enables you to view up to three of the images that were analysed to produce the AI findings.

Function	Details
Date	Displays the date that the X-ray machine recorded the images.
View	Indicates the view from which the image was taken.
Time	Displays the time that the X-ray machine recorded the image.

Image panel

The Image Panel is located on the left of the Findings List.

It displays the current image associated with the selected finding, including any localisation or laterality related to the finding (and its confidence level). It also enables you to access different views of the study.

The following functions display on the Image Panel:

Function	Details
View switcher	<p>The View switcher icons enable you to switch between image views.</p> <p>The following views are available for CXR studies:</p> <ul style="list-style-type: none"> • Frontal • Lateral <p>The following views are available for CTB studies:</p> <ul style="list-style-type: none"> • Axial • Sagittal • Coronal <p>The current view is highlighted.</p>
Finding name	The Finding name displays the name of the finding selected in the findings list.
Width/level (CTB only)	<p>The Width/level indicates the predetermined width and level of the selected greyscale spectrum:</p> <ul style="list-style-type: none"> • W – indicates window width • L – indicates window level
Window presets (CTB only)	<p>Window presets enable you to view the following pre-configured options (for CTB studies):</p> <ul style="list-style-type: none"> • Brain • Bone • Stroke • Subdural • Tissue <p>When you select an option, the associated width/level values display (see Width/level).</p> <p>The current window is highlighted.</p>
Slice scrollbar (CTB only)	<p>The Slice scrollbar enables you to scroll through all available slices for the current CTB study (see Scroll thumb/Current slice, below).</p> <p>If localisation is associated with the finding, the purple areas in the scrollbar indicate the areas of localisation in the study.</p>
Scroll thumb/Current slice (CTB only)	<p>The Scroll thumb/Current slice enables you to scroll through the images.</p> <p>It also indicates the current slice position in the slice scrollbar.</p>
Scroll direction (CTB only)	<p>The Scroll direction displays at both ends of the slice scrollbar.</p> <p>These indicators show the direction you are moving in as you scroll through the images.</p>

Function	Details
Localisation	If localisation is associated with the finding, it will display as a purple overlay over the relevant area in the image.
Laterality	If localisation cannot be localised to a specific area, laterality will be indicated by a purple Laterality arrow on the left, right (or bilateral) sides of the image.
Localisation toggle	<p>The Localisation toggle enables you to show or hide localisation for the current study.</p> <p><u>Note:</u> If you switch these options off, they will automatically switch on again as soon as you hover over either a Localisation or Laterality icon.</p>
Confidence bar	<p>The Confidence bar provides a visual indication of the likelihood that a particular finding is present.</p> <p>It enables you to see the relationship between the Confidence threshold and the 95% Confidence interval.</p>
Confidence threshold	<p>The Confidence threshold is the score below which the AI model is no longer confident that a finding is present.</p> <p>Your organisation will provide a pre-defined confidence threshold for each finding.</p>
Confidence Interval	<p>The 95% Confidence Interval is a fixed number that's added or subtracted to the calculated confidence score.</p> <p>It indicates the probability of the AI model reporting a false positive (i.e. not actually present in the image).</p>

Feedback mode functions

The following extra functions display on the Findings List and Image Panel while you are using the Annalise Viewer in 'feedback mode' (see [Provide feedback](#) on page 27).

Note: Feedback mode is only available if it has been enabled by your organisation.

Function	Details
Incorrect modality (CTB only)	The Incorrect modality button enables you to indicate that the study's modality has been incorrectly identified.
Add finding	The Add finding button enables you to add a finding that is missing from the study (i.e. was not identified by the AI model).
Reject finding	The Reject button enables you to reject a finding.
Undo Reject	The Undo Reject button enables you to 'unreject' a finding that you have rejected and reinstate it in the findings list.
Important find	<p>The Important find button displays when you hover your mouse over a finding. It enables you to flag an important finding that the AI model has identified, and which otherwise may have been missed. It.</p> <p>Note: This option is only available if your organisation has enabled the 'trial' feedback function.</p>
AI Feedback	<p>The AI feedback questions enable you to provide specific feedback about the Annalise Viewer.</p> <p>Note: This option is only available if your organisation has enabled the 'trial' feedback function. These questions can be customised for your organisation.</p>
Optional comments	<p>The Optional comments field enables you to provide additional feedback comments about the Annalise Viewer.</p> <p>Note: This option is only available if your organisation has enabled the 'trial' feedback function.</p>
Submit	<p>The Submit button enables you to save and submit any feedback you have added.</p> <p>Note: This option is only available if your organisation has enabled the 'trial' feedback function.</p>
Incorrect localisation	The Incorrect localisation button enables you to indicate that you believe localisation of the current finding is incorrect.

Security features

Annalise Enterprise includes security features which protect against unauthorised access and data modification.

These features ensure the secure authentication and encryption of sensitive data when transmitted between:

- the Annalise Enterprise Integration Adapter and the Annalise Enterprise Backend
- the Annalise Viewer and the Annalise Enterprise Backend
- the PACS Image Viewer and the Annalise Viewer (available when using the HTTPS interface)

It also includes the encryption of sensitive data stored in the Annalise Backend.

Getting started

Overview

This section shows you how to:

- run the Annalise Viewer Adaptor (if required)
- launch the Annalise Viewer
- access initial functions
- set your user preferences, and
- add your server settings.

Run Annalise Viewer Adapter

Depending on the type of PACS that you are using, you may need to run the Annalise Viewer Adapter to access the Annalise Viewer.

If you are using a Sectra IDS7 PACS, contact your system administrator to see whether the *Annalise Viewer Adapter for Sectra IDS7* has been installed on your computer.

For full details about installation and system requirements, refer to the *Annalise Enterprise Administration Guide*.

Launch Annalise Viewer

The Annalise Viewer will automatically launch once you have loaded a study in the PACS/RIS.

You can choose whether you want the Annalise Viewer to display automatically when you view a study in the PACS/RIS or you can open it manually (see below).

Once open, the Annalise Viewer displays the AI results for the current study.


1. Open the PACS/RIS worklist.

If the Annalise Viewer doesn't automatically display, you can either:

- open it manually, or
- update your user settings so that it displays automatically (if available).

Open Annalise Viewer manually

Either:

- open the Annalise Viewer via the **Start** menu on your computer, or
- click the  button on the PACS/RIS viewer menu bar.

Update settings to open Annalise Viewer automatically

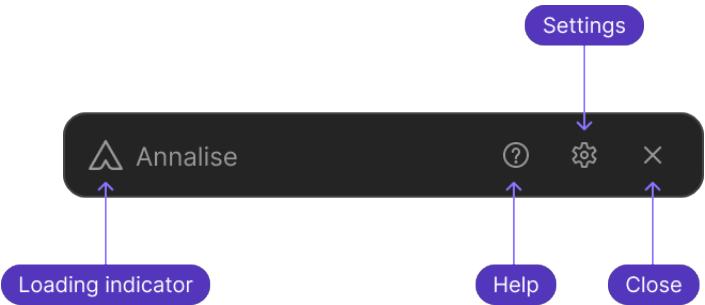
See [Automatically show findings](#) on page 22.

Access initial functions

The following section outlines the functions and actions that are available when you first launch the Annalise Viewer.

Study loading

The following will display if the study has not yet loaded:



Study loaded

Once the study has loaded, the findings list on the Annalise Viewer will either be collapsed or expanded, depending on the Settings options you choose.

See [Automatically show findings](#) on page 22.

Findings list collapsed

Annalise

Patient full-name86Y. M

PID: 11.11.11.11DOB: 13 Jan. 1933

> Chest X-ray8

ACC: 1.4.372.0.3.7691

Findings list expanded

Annalise

Patient full-name86Y. M

PID: 11.11.11.11DOB: 13 Jan. 1933

< Chest X-ray8

21 Jan. 2022 - 9:41:37 AM

2 images | ACC: 1.4.372.0.3.7691

PRIORITY4

< Peribronchial cuffing

< Simple effusion

< Scoliosis

< Spinal wedge fracture

OTHER4

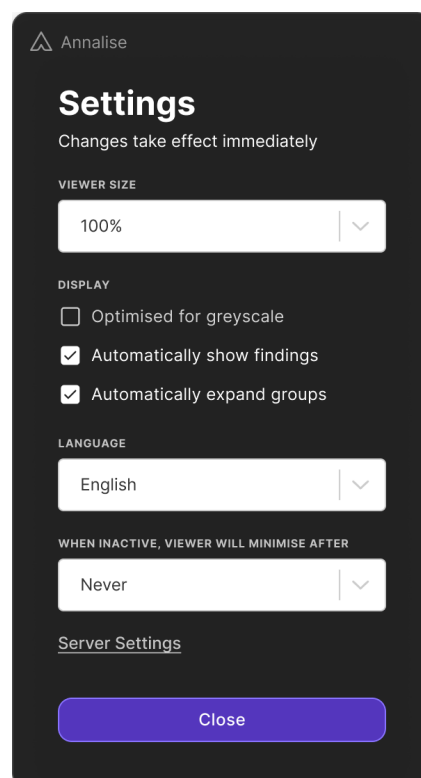
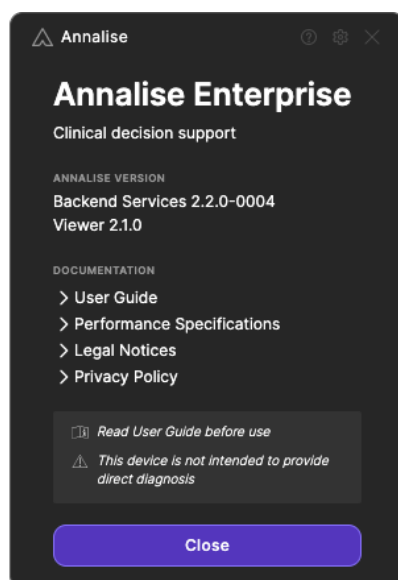
< Unfolded aorta

< Aortic arch calcification

< Spinal arthritis

< Abdominal clips

Action	Details
Loading indicator	When you first launch the Annalise Viewer, the Loading indicator will spin to indicate that the study is loading.
Access Help	Click the Help button to: <ul style="list-style-type: none"> view the Annalise version access the related <i>User Guide</i>, <i>Performance Specifications</i>, <i>Legal Notices</i> and <i>Privacy Policy</i> Click the Close button to return to the Annalise Viewer.
Set user preferences	Click the Settings button to: <ul style="list-style-type: none"> update your user preferences (see Set user preferences on page 22) add your server settings (see Add server settings on page 23) Click the Close button to return to the Annalise Viewer.
Close viewer	Click the Close button to minimise the Annalise Viewer so that it displays on your task bar. The viewer will automatically re-open when there are new AI findings to display.
Move viewer	To move the Annalise Viewer to another location or screen, click the viewer then drag it to the required position.
Close application	To close the application, right click the Annalise icon on your task bar then select Quit .

Help (*About* screen)**Settings** (*Settings* screen)

Set user preferences Follow these steps to access the *Settings* screen to select your user preferences.

1. Click the **Settings** button at the top right of the Annalise Viewer.
2. Select your user preferences as follows:

Option	Details
Viewer size	Click to select the size that you want the viewer to display on your screen.
Optimised for greyscale (CXR only)	This option enables you to optimise the greyscale image: <ul style="list-style-type: none">• if you select this option (for example, if your CXR radiography monitor is greyscale only), the user interface will remove reliance on colours to display findings• if you <u>don't</u> select this option, the user interface will use colour to highlight findings
Automatically show findings	This option enables you to automatically show findings when you are viewing a study: <ul style="list-style-type: none">• if you select this option, the Findings List will automatically display the findings• if you <u>don't</u> select this option (or if the automatic option is not available), you will need to manually expand the Findings List:<ul style="list-style-type: none">- open the Annalise Viewer (see Open Annalise Viewer manually on page 19)- click the Modality type on the Findings List (see Modality type on page 12)
Automatically expand groups	This option enables you to automatically expand all finding groups when the Findings List displays: <ul style="list-style-type: none">• if you select this option, all groups will be expanded• if you <u>don't</u> select this option, only the 'Priority' findings group (or your organisation's equivalent) will be expanded See Finding groups on page 13.
Language	Select the relevant language to display.
Inactive viewer minimise in	Select the inactive time period after which the viewer will be automatically minimised.

3. When you have finished, click **Close** to return to the Annalise Viewer.

Add server settings Follow these steps to add your server settings.

1. Click the **Settings** button at the top right of the Annalise Viewer.
2. At the bottom of the viewer, click **Server Settings**.
3. Type your **Organisation ID**, **Organisation Password** and **Annalise Server URL**.

Note: These details will be provided by annalise.ai.

4. When you have finished, click **Test** to check your settings.

If 'Connected' displays	You have successfully connected to the server.
If a 'Not connected' message displays	Check that you have entered the details correctly and try again. If you are still having problems, contact the annalise.ai Professional Services Team.

5. Once you have connected successfully, click **Save**.
6. On the Settings screen, click **Close** to return to the Annalise Viewer.

Using the Annalise Viewer

Review AI findings

The Annalise Viewer displays the suspected radiological findings for a study in the Findings List (the results that display depend on the configuration set by your organisation).

This section shows you how to:

- verify the patient's details
- review the findings
- interpret the confidence level of each finding

Verify patient details

1. Launch the Annalise Viewer.
See [Launch Annalise Viewer](#) on page 19.
2. To verify the patient's details, check that the Patient ID (**PID**) and Accession No. (**ACC**) on the Findings List match those on the study loaded in the PACS viewer.

Review the findings

Multiple findings with varying degrees of confidence may display. In these instances, it is important to use your clinical judgement when reviewing all findings.

1. Use the following functions to help you review the findings:

Function	Details
Show images analysed for the current study	<p>Select a finding in the findings list to display it in the Image Panel.</p> <ul style="list-style-type: none"> • For <u>CXR</u> studies, you can view: <ul style="list-style-type: none"> - both the current image in the Image Panel, and - up to three other images that have been analysed for the current study (click the Study details on the Findings List to display these images) <p>See Study Details Panel (CXR only) on page 8.</p> • For <u>CTB</u> studies, all of the images display in the Image Panel. Click and drag the Scroll thumb (or use your mouse wheel) to scroll through these images. <p>See:</p> <ul style="list-style-type: none"> - Scroll thumb/Current slice on page 15 - Slice scrollbar on page 15

continued

Function	Details
Switch between views	<p>On some clinical findings, the regions of interest may be highlighted on multiple views.</p> <p>To switch between views, click the View Switcher to navigate to other available views (the highlighted icon indicates the active view).</p> <p>For CTB studies, you can also use the Width/level to view the relevant pre-configured window presets.</p> <p>See:</p> <ul style="list-style-type: none"> • View switcher on page 15 • Width/level on page 15
Identify the number of findings present	<p>A number displays in the following locations to indicate the number of findings identified by the AI model:</p> <ul style="list-style-type: none"> • beside the Modality type (total number of findings), and • next to each findings group (total for that group). <p>See Finding count on page 12.</p> <p>Click the down arrow beside any findings with shared localisations to view all associated findings (see Shared localisations on page 13).</p>
Review regions of interest (ROI)	<p>If present, regions of interest (ROI) will be highlighted on the image displayed in the Image Panel.</p> <p>Note: The Localisation toggle must be switched on to view localisation or laterality (see Localisation toggle on page 16).</p>
<i>View localisation</i>	<p>If localisation is associated with a finding, a Localisation icon will display next to the finding name in the Findings List and a purple overlay will display on the image when you select the finding.</p> <p>For CTB studies, you can also use the scroll thumb to scroll through the areas highlighted in purple on the slice scrollbar.</p>
<i>View laterality</i>	<p>If the finding is not localised to a specific area, a Laterality icon will display next to the finding name in the Findings List and a purple arrow (or arrows) will display on the image when you select the finding.</p>
<i>Localisation does not display</i>	<p>If the AI model indicates that a finding is present and its location is obvious to the clinician, localisation will not display for that finding (and the Localisation icon will not show in the Findings List).</p> <p>To check which findings display localisation, see the Findings list on page 32.</p>
Switch localisation/laterality option on or off	<p>To switch the localisation/laterality option on or off, click the Localisation toggle at the bottom of the Image Panel.</p> <p>See Localisation toggle on page 16.</p>

Interpret the confidence level

Your organisation will provide a pre-defined confidence threshold for each finding. For a finding to be considered present in the study, it must therefore have a score greater than this threshold.

For each finding, the AI model provides:



- a prediction score, and
- a 95% confidence interval.

This information is displayed on the confidence bar on the Image Panel.

See:

- [Confidence bar](#) on page 16
- [Confidence threshold](#) on page 16
- [Confidence Interval](#) on page 16

Refer to the following examples:

Confidence level	Interpretation
Higher confidence	<ul style="list-style-type: none">• The prediction score is above the confidence threshold• The confidence interval is above the confidence threshold• The finding is most likely present in the study
	
Lower confidence	<ul style="list-style-type: none">• The prediction score is above the confidence threshold• The lower border of the confidence interval is below the confidence threshold• The finding may be present in the study
	

Provide feedback

If enabled by your organisation, the feedback function enables you to provide feedback about the AI model's performance.

While using the Annalise Viewer, you can flag:

- an incorrect study
- an incorrect localisation

You can also add missing findings, reject findings and mark findings as an 'important find'.

Depending on the feedback mode enabled by your organisation, the following options will either display by default or you will need to manually switch to feedback mode.

1. If the feedback options don't automatically display, go to the bottom right of the Findings List and click the **Feedback** button.
2. Refer to the table below to determine the feedback you would like to provide and the steps to follow.

Option	Steps
Flag an incorrect study	<p>If a study's modality has been incorrectly identified, click the Incorrect modality button at the top of the Findings List.</p> <p>To undo this action, click the button again to remove the flag.</p>
Flag an incorrect localisation	<p>If you feel that the localisation of the current finding is incorrect, click the Incorrect localisation button at the bottom right of the Image Panel.</p> <p>A flag will display to the right of the finding on the Findings List.</p> <p>To undo this action, click the button on the Image Panel again to remove the flag.</p>
Add a missing finding	<p>If a finding is missing from the study:</p> <ol style="list-style-type: none"> 1. Click Add Finding at the bottom of the Findings List 2. Type the name of the finding in the Enter Finding field <ul style="list-style-type: none"> - if the finding displays, click to select the finding - if the finding <u>doesn't</u> display, type the full name of the finding, then click Add New <p>The new finding will display under the <i>User added</i> finding group.</p> <p>See Finding groups on page 13.</p>
Reject an incorrect finding	<p>If you determine that an AI finding is not present in the study, click the Reject button beside the finding name.</p> <p>The finding name will display as strikethrough text.</p>
Undo a rejected finding	<p>If you have rejected a finding but want to undo this action (and reinstate the finding in the findings list), click the Undo Reject button beside the finding name.</p>

continued

Option	Steps
Mark a finding as an 'important find'	If you determine that the AI model has identified an important finding that may otherwise have been missed, click the Important find button.
Feedback questions	Click to select any question/s if they apply. <u>Note:</u> These questions can be customised for your organisation.
Provide extra comments	Type any extra comments in the Optional Comments field.

3. To save and submit your feedback, either:
- click the **Feedback** button again (your feedback will also be saved automatically when you move to a new study), OR
 - click **Submit**.

Note: The option that displays is determined by the feedback mode enabled for your organisation.

Troubleshooting

Problems and solutions

If you have issues with the Annalise Enterprise application, refer to the following table.

If you are unable to resolve the issue, contact the annalise.ai Professional Services Team.

Problem	Solution
Missing server settings Organisation details are incomplete.	Contact the annalise.ai Professional Services Team.
Application unresponsive After loading a study in the PACS viewer, the Annalise Viewer does not respond.	Follow these steps: <ol style="list-style-type: none"> 1. Check that the study is a CR, DX or CT brain. 2. Check that the PACS viewer version is compatible with the Annalise Viewer. 3. Quit the Annalise Viewer, then open it again. 4. Attempt to re-load the study. If the problem persists, contact the annalise.ai Professional Services Team.
Application unresponsive with Sectra PACS The Annalise Viewer is unresponsive when a study is loaded. Sectra PACS warns the viewer is out of sync.	Follow these steps: <ol style="list-style-type: none"> 1. Ensure the Annalise Viewer Adapter is running in the System Tray. 2. Ensure the Sectra Desktop Sync functionality is enabled. 3. Quit then restart the Annalise Viewer Adapter. If required, contact your internal IT support team for assistance.
Unexpected finding change When viewing a study, the AI findings change unexpectedly.	Some software systems may encounter this error when viewing studies in multiple windows. The Annalise Viewer will synchronise with the currently selected window. Ensure that the shortcut key mapping in the PACS viewer is mapped correctly.
Out of scope study After loading a study in the PACS viewer, either of the following errors display: <ul style="list-style-type: none"> • <i>'Must be 16yrs+ for AI analysis'</i> • <i>'Must be 18yrs+ for AI analysis'</i> 	Annalise Enterprise only supports studies for patients who are: <ul style="list-style-type: none"> • 16 years or older (for CXR), or • 18 years or older (for CTB). Annalise Enterprise uses DICOM tags to determine age.
Maintenance The following message displays: <i>'Maintenance in progress. annalise.ai will be available soon'</i>	The application is currently undergoing maintenance. Once maintenance is complete, you will be able to use the application as normal.

continued

Problem	Solution
<p>Out of scope study</p> <p>After loading a study in the PACS viewer, one of the following errors displays in the Annalise Viewer:</p> <ul style="list-style-type: none"> • <i>'PA/AP image required for AI analysis'</i> • <i>'Chest X-ray required for AI analysis'</i> • <i>'Study not supported'</i> • <i>'Unable to detect a non-contrast brain series'</i> • <i>'Slice thickness not supported'</i> • <i>'Unable to detect series for processing'</i> <p>Error codes: 007, 008, 032, 033, 034, 035, 036, 037, 038, 039, 040, 041, 042, 043, 044, 045, 046, 047, 048, 049, 050, 051</p>	<p>The study does not meet the minimum requirements for AI processing:</p> <ul style="list-style-type: none"> • Annalise Enterprise only supports studies containing chest X-rays or brain CT scans • the study must contain at least one PA or AP image or supported CT views <p>The Annalise Enterprise includes an AI feature that determines whether:</p> <ul style="list-style-type: none"> • the image is a chest X-ray or brain CT, and • if there is a PA or AP image or supported brain image. <p>AI models have an error margin. On rare occasions, Annalise Enterprise will not recognise a chest X-ray or brain CT and this error will display.</p> <p>For further details, contact the annalise.ai Professional Services Team and quote the error code.</p>
<p>Not processing</p> <p>After loading a study in the PACS viewer, the following message displays in the Annalise Viewer: <i>'Results pending...'</i></p>	<p>The study is currently being analysed.</p> <p>The application will wait for up to one minute for results.</p> <p>If the problem persists, contact your internal IT support team.</p>
<p>Error 004</p> <p>After loading a study in the PACS viewer, the following message displays in the Annalise Viewer: <i>'Cannot reach Annalise.au servers: (Error: 004) Please contact support'</i></p>	<p>Check your internet connection.</p> <p>If your internet connectivity is OK and the problem continues, contact your internal IT support team.</p>
<p>No results</p> <p>After loading a study in the PACS viewer, the following error displays in the Annalise Viewer: <i>'No results available'</i></p>	<p>Either the study is not supported or the study may not have reached the Annalise Enterprise Integration Adapter.</p> <p>If the study was recently performed, it may not have been forwarded to Annalise Enterprise.</p> <p>If the problem continues, contact your internal IT support team.</p>
<p>Study processing</p> <p>After loading a study in the PACS viewer, the following error code displays in the Annalise Viewer: <i>'Error: 029'</i></p>	<p>The study has not yet completed AI processing. Wait for a while and try again.</p> <p>If the problem continues, contact your internal IT support team.</p>
<p>Other error codes</p> <p>After loading a study in the PACS viewer, one of the following error codes displays in the Annalise Viewer: 001, 002, 003, 009, 010, 011, 014, 015, 016, 020, 021, 022, 026, 027, 031, 099</p>	<p>Technical product error.</p> <p>Contact the annalise.ai Professional Services Team and quote the error code.</p>

Support and feedback

Refer to the following table for support and feedback details:

Support type	Details
Technical support and feedback	Email support@annalise.ai
Product feedback and complaints	<p>Report any product feedback and complaints related to Annalise Enterprise to the Annalise Quality team at email QA@annalise.ai.</p> <p>Any serious incidents related to Annalise Enterprise should be reported to annalise.ai and the competent authority or regulatory authority in which the user and/or patient is established:</p> <ul style="list-style-type: none"> • Australia: www.tga.gov.au • New Zealand: www.medsafe.govt.nz • Member States of the European Union: ec.europa.eu/health/medical-devices-sector/new-regulations/contacts_en
Product performance and administration guides	Check our website: annalise.ai/guides

Appendices

Findings list

The clinical development of the Annalise CXR and Annalise CTB ontology trees enabled Annalise Enterprise to identify a comprehensive list of radiological findings that would be most clinically necessary and helpful to clinicians.

These findings are referred to as the 'findings list'.

For information on the performance of the AI model, refer to the *Annalise Enterprise Performance Guide*.

Annalise CXR ontology tree

CXR finding	Localisation available	Definition
Abdominal clips	No	Surgical clips in the abdomen.
Acute clavicle fracture	Yes	Cortical breach of a clavicle. May be difficult to see if nondisplaced. No callus formation for acute fractures.
Acute humerus fracture	Yes	Cortical breach of the humerus, usually at the surgical neck of humerus.
Acute rib fracture	Yes	Cortical breach of a rib without callus formation or union, does not include surgical rib resection or thoracotomy.
Airway stent	No	Stents within the trachea or bronchi.
Aortic arch calcification	No	Calcification of the aortic arch. Does not include mitral valve calcification, descending aortic or pericardial calcification. Only includes Grade 2 or 3 calcification (i.e. thick calcification).
Aortic stent	No	Stent/graft in the aorta.
Atelectasis	Yes	Includes subsegmental collapse, linear and bibasal atelectasis.
Axillary clips	Yes	Surgical clips in the axilla.
Basal interstitial thickening	No	Opacities within pulmonary lobules in a linear/branching pattern affecting predominantly lower zones of one or both lungs. This also includes thickened chronic fibrotic changes from lung scarring. This finding may still be predicted if there are upper zone changes as long as the pattern is lower zone predominant.
Biliary stent	No	Stents within the biliary tree.

CXR finding	Localisation available	Definition
Breast implant	No	Breast prosthesis usually of gel-like material implanted behind or in place of the female breast as cosmetic or reconstructive surgery.
Bronchiectasis	No	Dilation of the bronchi which can be localised or diffuse.
Calcified axillary nodes	No	Calcified soft tissue density in the axilla.
Calcified granuloma (< 5mm)	Yes	Calcified intraparenchymal lesion or lesions which are smaller than 5mm.
Calcified hilar lymphadenopathy	No	Calcified lymph nodes in hilum.
Calcified mass (> 5mm)	Yes	One or more intraparenchymal lesions (>5mm) which may be partially or completely calcified.
Calcified neck nodes	No	Calcified soft tissue density in the neck.
Calcified pleural plaques	No	Calcified thickening along the pleura at the diaphragm, lateral thoracic wall, or apex.
Cardiac valve prosthesis	No	Replacement of native cardiac valve. Includes transcatheter aortic valve implantation.
Cavitating mass(es)	Yes	Lucent walled lesion which arises from a solid lesion that then develops gas within it. As a result, the wall is typically thickened.
Cavitating mass with content	Yes	Collection of air with air fluid level or in crescent shape that separates the wall of a cavity from an inner mass.
Cervical flexion	No	The chin is visible and obscuring the apex of the lung or superior mediastinum. Only the primary AP or PA view is assessed, not the Lateral view or any other view/post-processed image.
Chronic clavicle fracture	No	Corticated clavicle fractures with surrounding callus formation or union.
Chronic humerus fracture	No	United, malunited or non-united humerus fracture.
Chronic rib fracture	No	Cortical breach of a rib with surrounding callus formation or union.
Clavicle fixation	Yes	Internal fixation of clavicle fractures. When a fracture has been fixed, the acute clavicle fracture may not be predicted.
Clavicle lesion	Yes	Sclerotic or lytic, malignant or benign lesion within the clavicle with or without pathological fracture. This includes lesions due to systemic conditions such as myeloma, osteogenesis imperfecta, renal osteodystrophy etc.

CXR finding	Localisation available	Definition
Coronary stent	No	Stents within the coronary arteries.
Diaphragmatic elevation	No	<p>Left hemidiaphragm is higher than the right or if the right is more than 3cm higher than the left.</p> <p>This finding only applies to the inspiratory view, not the lateral or expiratory views.</p>
Diaphragmatic eventration	No	<p>Abnormal contour of the diaphragm affecting only a segment of the hemidiaphragm.</p> <p>Contrast this with diaphragmatic elevation which affects the entire hemidiaphragm.</p>
Diffuse airspace opacity	Yes	Diffuse ill-defined airspace/ground glass opacity or consolidation throughout one or both lungs.
Diffuse bullae	No	Multiple large lucencies due to emphysema in the upper and lower zones of one or both lungs.
Diffuse fibrotic volume loss	Yes	<p>Opacities within pulmonary lobules in a linear/branching fashion affecting one or both lungs. Upper and lower zones affected.</p> <p>Associated with volume loss (hilar displacement, diaphragmatic elevation, tracheal displacement).</p> <p>This also includes thickened chronic fibrotic changes from lung scarring.</p>
Diffuse interstitial thickening	Yes	<p>Opacities within pulmonary lobules in a linear/branching pattern affecting both upper and lower zones of one or both lungs.</p> <p>This also includes thickened chronic fibrotic changes from lung scarring.</p>
Diffuse lower airspace opacity	Yes	<p>Diffuse ill-defined airspace/ground glass opacity or consolidation in predominantly the lower zones of one or both lungs.</p> <p>Does not include interstitial opacities. This finding may still be predicted if there are upper zone changes as long as the pattern is lower zone predominant.</p>
Diffuse nodular/miliary lesions	Yes	Multiple tiny lung opacities of one or both lungs. Usually innumerable and too small to measure. May be calcified.
Diffuse pleural thickening	No	<p>Pleural masses/opacities in multiple locations. Pleural mass is distinguished from intraparenchymal mass by having an obtuse angle with the pleura.</p> <p>Diffuse nodular pleural thickening must affect more than half the lung height or be bilateral and must be greater than 1cm in maximal thickness.</p>

CXR finding	Localisation available	Definition
Diffuse spinal osteophytes	No	Flowing osteophytes at the anterior or right lateral vertebral body connecting at least four contiguous vertebrae. Typically, smooth and thin connections.
Diffuse upper airspace opacity	Yes	Diffuse ill-defined airspace/ground glass opacity or consolidation in predominantly the upper zones of one or both lungs. Does not include interstitial opacities. This finding may still be predicted if there are lower zone changes as long as the pattern is upper zone predominant.
Distended bowel	No	Pathologically distended small or large bowel loops or stomach. Small bowel loops must measure > 3cm and large bowel loops > 6cm, or if the stomach causes mass effect upon the diaphragm. Air fluid levels may be present on erect view.
Electronic cardiac devices	No	Pacemakers, pacing wires (internal or external), internal defibrillators and loop recorders. ECG leads do not count as electronic cardiac devices.
Focal airspace opacity	Yes	Single area of consolidation or air space/ground glass opacity in the lung. Air bronchogram may be present.
Gallstones	No	Calcified RUQ stones projected over the gallbladder.
Gastric band	No	Band around the gastro-oesophageal junction.
Hiatus hernia	No	Sliding or paraoesophageal hiatus hernia into the posterior mediastinum. Retrocardiac fluid level may be present.
Hilar lymphadenopathy	No	Increase in size and density of the hila with loss of normal hilar angle.
Humeral lesion	Yes	Sclerotic or lytic, malignant or benign lesion within the humerus with or without pathological fracture. This includes lesions due to systemic conditions such as myeloma, osteogenesis imperfecta, renal osteodystrophy etc.
Hyperinflation	No	Increased total lung volumes as evidenced by flattening of the diaphragm or increased retrosternal clear space on lateral view (or both).
Image obscured	No	Image obscured by object.

CXR finding	Localisation available	Definition
Incompletely imaged chest	No	Part of the lungs not included in the image. This finding may be predicted if any image in the series is incomplete.
Inferior mediastinal mass	No	Masses within the mediastinum with the centre of the mass below the superior border of the aortic arch.
Intercostal drain	Yes	This finding could mean either of the following: <ul style="list-style-type: none"> Malpositioned intercostal drain: ICC with tip or side holes not within the pleural cavity, typically migrates out into the soft tissue In position intercostal drain: Catheter within the pleural space to drain fluid and/or gas
In position Central Line (CVC)	Yes	Internal jugular lines, subclavian lines and peripheral inserted catheters (PICC). Central venous lines should be placed with the tip in the SVC/cavoatrial junction. The line should not be in the brachiocephalic, subclavian veins, or right atrium.
In position Endotracheal Tube (ETT)	No	Endotracheal or tracheostomy tube within the trachea for ventilation. Needs to be 3 to 7cm above the carina.
In position Nasogastric Tube (NGT)	Yes	Enteric tube from the mouth/nose into the stomach for feeding or drainage.
In position Pulmonary Arterial Catheter (PAC)	No	Pulmonary artery catheter with tip within the pulmonary artery or main pulmonary trunk.
Internal foreign body	Yes	Non-surgical internal foreign bodies such as inhaled foreign bodies, gunshot shrapnel that is internal to the patient. This must be inside the patient and not a medical device. Does not include ECG leads or other objects that are external to the patient.
Kyphosis	No	Increased kyphosis of the thoracic spine with Cobb angle greater than 45 degrees on lateral view. Usually predicted off the lateral view.
Loculated effusion	Yes	Fluid within the pleural cavity that is trapped within a fissure or at the apex or lateral wall on an erect view.
Lower zone bullae	No	Multiple large lucencies due to emphysema in the lower zones of one or both lungs. This finding may still be predicted if there are upper zone changes as long as the pattern is lower zone predominant.

CXR finding	Localisation available	Definition
Lower zone fibrotic volume loss	Yes	Opacities within pulmonary lobules in a linear/branching pattern affecting one or both lungs. Lower zone predominant. Associated with volume loss (diaphragmatic elevation). This also includes thickened chronic fibrotic changes from lung scarring. This finding may still be predicted if there are upper zone changes as long as the pattern is lower zone predominant.
Lung collapse	Yes	Collapse of the entire lung, or most of the lung.
Lung sutures	No	Suture material within then lung parenchyma which is typically post lung resection.
Mastectomy	No	Absence or asymmetry of breast shadows suggesting mastectomy or partial mastectomy.
Mediastinal clips	No	Surgical clips in the mediastinum or hilum. Typically, small clips from coronary artery bypass grafts. Hilar clips from lung surgery also fall under this category.
Multifocal airspace opacity	Yes	Multiple area of ill-defined airspace/ground glass opacity or consolidation.
Multiple masses or nodules	No	More than one pulmonary mass/nodule.
Neck clips	Yes	Any surgical clips in the neck.
Nipple shadow	No	Rounded well defined density projected over the expected locations of the nipple, sometimes bilateral. Must be prominent enough to be confused for a lesion.
Oesophageal stent	No	Stents within the oesophagus.
Osteopaenia	No	Severe reduced apparent bone density of the vertebrae such that there is difficulty distinguishing between bone and adjacent soft tissues even when windowing appropriately. Usually predicted off the lateral view.
Overexposed	No	Unable to see lung markings even after appropriate windowing. Only the primary AP or PA view is assessed, not the Lateral view or any other view/post-processed image.

CXR finding	Localisation available	Definition
Patient rotation	No	<p>The spinous process is laterally displaced by more than a quarter of the interclavicular distance.</p> <p>Only the primary AP or PA view is assessed, not the Lateral view or any other view/post-processed image.</p> <p>If the patient is severely scoliotic, this finding may be unreliable.</p>
Pectus carinatum	No	<p>Congenital chest wall deformity with anterior protrusion of the sternum.</p> <p>Only the primary AP or PA view is assessed, not the Lateral view or any other view/post-processed image.</p>
Pectus excavatum	No	<p>Congenital chest wall deformity with concave depression of the sternum.</p> <p>Only the primary AP or PA view is assessed, not the Lateral view or any other view/post-processed image.</p>
Peribronchial cuffing	No	<p>Thickening of the bronchial wall without dilation of the bronchial lumen.</p>
Pericardial fat pad	No	<p>Fat pad adjacent to the heart border. Can be mistaken for consolidation by referrers.</p>
Perihilar airspace opacity	Yes	<p>Diffuse perihilar airspace/ground glass opacity of one or both lungs.</p> <p>Does not include interstitial opacities. This finding can still be predicted if there are other changes as long as the pattern is perihilar predominant.</p>
Pleural mass	Yes	<p>Pleural mass/opacity in one location. Pleural mass is distinguished from intraparenchymal mass by having an obtuse angle with the pleura. A pleural mass is either nodular thickening of the pleura or pleural thickening greater than 1cm.</p> <p>The pleural mass should affect less than half the lung height and unilateral. Local pleural thickening less than 1cm is usually ignored.</p>
Pneumomediastinum	No	<p>Gas within the mediastinum, typically outlining the pericardium and mediastinal margin.</p>
Post resection volume loss	Yes	<p>Volume loss due to resection of lung e.g. pneumonectomy, lobectomy or segmentectomy, usually with staples/clips visible.</p>
Pulmonary artery enlargement	No	<p>Enlargement of the pulmonary artery typically with loss of the aortopulmonary window.</p> <p>Width of the right descending pulmonary artery > 17mm on the PA film.</p>

CXR finding	Localisation available	Definition
Pulmonary congestion	No	Upper lobe diversion with loss of tapering of vessels towards the apices with upper zone vessels having similar or larger diameter compared to lower zone. Only reliable on erect views.
Reduced lung markings	No	Reduced lung markings. Distinguished from bullae as bullae will have a thin wall.
Rib fixation	Yes	Internal fixation of rib fractures. May not be predicted if the fracture has been fixated.
Rib lesion	Yes	Sclerotic or lytic, malignant or benign lesion within the rib with or without pathological fracture. This includes lesions due to systemic conditions such as myeloma, osteogenesis imperfecta, renal osteodystrophy etc. Congenital rib anomalies such as bifid or fused ribs are not included.
Rib resection	No	Surgical removal of ribs - may be multiple. Typically, thoracotomies are performed for lung resection.
Rotator cuff anchor	Yes	Bone anchors within the humeral heads.
Scapular fracture	Yes	Cortical breach of the scapula. This includes both acute and chronic fractures.
Scapular lesion	Yes	Sclerotic or lytic, malignant or benign lesion within the scapula with or without pathological fracture. This includes lesions due to systemic conditions such as myeloma, osteogenesis imperfecta, renal osteodystrophy etc.
Scoliosis	No	Increased lateral curvature of the thoracic spine with Cobb angle greater than 10 degrees on frontal view.
Segmental collapse	Yes	Collapse of entire segment or lobe of the lung, or compressive collapse from adjacent pleural effusion.
Shoulder arthritis	No	Loss of joint space, osteophyte formation, sclerosis and degenerative changes of the glenohumeral joint. Usually only predicted if there are significant changes – i.e. near complete loss of joint space.
Shoulder dislocation	Yes	Humeral head not articulating with glenoid fossa. Typically, anterior and inferior dislocation.

CXR finding	Localisation available	Definition
Shoulder fixation	Yes	Internal fixation of humerus or scapula fractures. May not be predicted if the fracture has been fixated.
Shoulder replacement	Yes	Total, partial or reverse total shoulder replacement.
Simple effusion	Yes	Fluid within the pleural cavity. In an erect radiograph this accumulates at the base. May form a meniscus.
Simple pneumothorax	Yes	Air within the thoracic cavity outside of the lung. May be associated with lung edge.
Solitary lung mass	Yes	Single rounded well-defined opacity. Measures 3cm or larger.
Solitary lung nodule	Yes	Single rounded well-defined opacity. Measures less than 3cm.
Spinal fixation	No	Internal fixation of the spine for fractures or degeneration.
Spinal arthritis	No	Near complete loss of intervertebral space, fusion of vertebrae, or heavy calcification of intervertebral discs at multiple levels.
Spinal lesion	Yes	Sclerotic or lytic, malignant or benign lesion within the thoracic spine with or without pathological fracture. This includes lesions due to systemic conditions such as myeloma, osteogenesis imperfecta, renal osteodystrophy etc.
Spinal wedge fracture	Yes	Acute or chronic compression, wedge, distraction or translated fractures. Typically seen on lateral view. Usually chronicity cannot be reliably assessed so this is not differentiated. For compression or wedge fractures, there must be more than 20% loss in anterior height or central height as measured to the nearest normal vertebra or posterior vertebral body height (whichever is larger).
Sternotomy wires	No	Metallic wires fixating a sternotomy.
Subcutaneous emphysema	Yes	Air within the soft tissues outside the abdominal or thoracic cavity. May be associated with pneumothorax or pneumomediastinum.
Subdiaphragmatic gas	No	Gas below the diaphragm not contained within a lumen.

CXR finding	Localisation available	Definition
Suboptimal Central Line (CVC)	Yes	CVC or PICC line where the tip of the catheter is not positioned at the cavoatrial junction or the distal SVC, or if the catheter is looped or kinked.
Suboptimal Endotracheal Tube (ETT)	No	Endotracheal or tracheostomy tube that is too close to the carina or too far from it (not within 3 to 7cm), or within a bronchus.
Suboptimal gastric band	No	Band around the gastro-oesophageal junction with phi angle between the band and the spine not within 0 to 60 degrees. Malpositioned bands may be associated with oesophageal dilation.
Suboptimal Nasogastric Tube (NGT)	Yes	NGT where the tip and the side holes are not projected within the stomach, or the tip of the NGT is not visible and the image is cut-off within 5cm of the gastro- oesophageal junction. May be within the oesophagus or bronchus.
Suboptimal Pulmonary Arterial Catheter (PAC)	No	Pulmonary artery catheter with tip not in the main pulmonary trunk or pulmonary arterial branch e.g. in the right ventricle, or if the catheter is looped or kinked.
Superior mediastinal mass	No	Masses within the mediastinum with the centre of the mass above the superior border of the aortic arch/loss of paratracheal stripes. If the patient is supine or rotated, the superior mediastinum can be widened due to benign causes such as venous distension or projection.
Tension pneumothorax	Yes	Air within the thoracic cavity outside of the lung. May be associated with lung edge. Resultant mediastinal shift.
Tracheal deviation	No	Moving of the trachea across to one side secondary to increased pressure on one side or decreased pressure on the other side. Consideration of the extent of patient rotation must be taken into account.
Underexposed	No	Outline of any thoracic vertebral bodies not visible. Only the primary AP or PA view is assessed, not the lateral view or any other view/post-processed image.
Underinflation	No	The diaphragm is projected above the 9th posterior rib in a PA view or above the 7th rib in an AP view. Only reliable for inspiratory films. When this finding is predicted usually both lungs are underinflated.

CXR finding	Localisation available	Definition
Unfolded aorta	No	Widening of the aortic curve while maintaining a normal aortic diameter.
Upper interstitial thickening	Yes	Opacities within pulmonary lobules in a linear/branching pattern affecting predominantly upper zones of one or both lungs. This also includes thickened chronic fibrotic changes from lung scarring. This finding can still be predicted if there are lower zone changes as long as the pattern is upper zone predominant.
Upper zone bullae	No	Multiple large lucencies due to emphysema in the upper zones of one or both lungs. This finding may still be predicted if there are lower zone changes as long as the pattern is upper zone predominant.
Upper zone fibrotic volume loss	Yes	Opacities within pulmonary lobules in a linear/branching pattern affecting one or both lungs. Upper zone predominant. Has associated volume loss (hilar elevation). This also includes thickened chronic fibrotic changes from lung scarring. Includes apical scarring e.g. from previous TB. This finding can still be predicted if there are lower zone changes as long as the pattern is upper zone predominant.
Widened aortic contour	No	Widening of the aortic arch diameter to 4.5cm or greater or the descending aorta to 4cm or greater, typically due to aneurysm, dissection or rupture.
Widened cardiac silhouette	No	Increased cardiothoracic ratio > 0.5 on PA view and > 0.6 on AP view. Includes cardiomegaly and enlarged cardiac silhouette due to pericardial effusion. Measurement of heart diameter is taken from a single measurement, parallel to the measurement of the maximal diameter of the thoracic cage from the inner ribs. This finding is unreliable if the lungs are underinflated.

Annalise CTB ontology tree

CTB finding	Localisation available	Definition
Abnormal prominent vessels	Yes	Prominence of vessels in the brain or along the surface of the brain, consistent with a vascular malformation. May contain haemorrhage.
Acute brainstem infarct	Yes	Acute hypodensity of brainstem (within two weeks).
Acute cerebellar infarct	Yes	Hypodensity of cerebellum in vascular distribution or with history consistent with acute infarct. Subacute infarct is also included if under two weeks old or maintains mass effect. This does not include old infarcts.
Acute cerebral infarct	Yes	Acute infarct in any cerebral artery territory secondary to thrombo-embolism, vasospasm, vascular compression or dissection.
Acute haemorrhagic infarct	Yes	Acute infarct in any cerebral artery territory containing frank haemorrhage
Acute infarct petechial haemorrhage	Yes	Acute infarct in any cerebral artery territory containing petechial haemorrhage.
Acute intraparenchymal haemorrhage	Yes	Acute haematoma (hyperdense), in the cerebral hemispheres (including basal ganglia and periventricular), brainstem or cerebellum.
Acute lacunar infarct	Yes	Mild ill-defined hypodensity of basal ganglia, thalami or deep white matter consistent with acute lacunar infarct. This does not include old lacunar infarcts.
Acute on chronic subdural haematoma	Yes	Mixture of hyperdense and hypodense crescent shaped subdural haematoma extending over the cortical surface of the brain.
Acute peripheral infarct	Yes	Small acute hypodensities of cortex or subcortical white matter due to small infarcts, usually from a central embolic cause or fragmented emboli from large vessel.
Acute subdural/extradural haematoma	Yes	Hyperdense crescent shaped haematoma extending over the cortical surface of the brain.
Acute watershed infarct	Yes	Acute infarct in deep and/or superficial watershed distributions between vascular territories, usually from thrombo-embolic disease, global hypotension or vasospasm.
Aggressive bone lesion	Yes	Lytic bone lesion in calvarium with favoured aggressive appearances (wide zone of transition, aggressive periosteal reaction).

CTB finding	Localisation available	Definition
Aggressive extra-axial mass of soft tissue	Yes	Aggressive mass in the extra-axial space, typically a Grade II or III meningioma, haemangiopericytoma, or dural metastasis. Invades into skull or causes aggressive periosteal reaction.
Aggressive meningeal thickening	Yes	Localised or nodular dural thickening, greater than 5mm in thickness, may be associated with vasogenic oedema. Includes leptomeningeal carcinomatosis.
Aggressive skin lesion	Yes	Soft tissue density thickening of the scalp or skin in face or neck with aggressive features such as osseous invasion.
Air fluid level paranasal sinuses	No	Acute fluid collection or blood in the paranasal sinuses.
Aneurysm	Yes	Rounded density in the region of a vessel, consistent with an aneurysm.
Aneurysm coils	No	Metallic coils placed within the lumen of an aneurysm.
Arachnoid cyst	Yes	Subdural or extradural collection of CSF density e.g. arachnoid cyst or pseudomeningocele, or epidermoid cyst.
Basal ganglia and dentate calcification	No	Calcification of the basal ganglia and dentate nuclei, usually physiological, due to aging but can be pathological e.g. metabolic disorders or Fahr's disease. Usually only predicted if more than 4 small specks, each of size > 3mm, or at least one single larger speck > 5 mm in length.
Cerebellar atrophy	No	Prominent cerebellar fissures and enlarged 4th ventricle due to volume loss of cerebellar parenchyma disproportionate to the patient's age.
Cerebral atrophy	No	Prominent sulci and enlarged ventricles due to volume loss of cerebral parenchyma.
Cerebral convexity subarachnoid haemorrhage	Yes	Hyperdensity in subarachnoid space at the cerebral convexity sulci.
Chiari malformation	Yes	Cerebellar tonsillar ectopia extending 5 or more mm below foramen magnum.
Chronic globe abnormality	Yes	Elongation of the globe due to scleral thinning (staphyloma) or protrusion of the globe through scleral defect (coloboma). Shrunken globe due to phthisis bulbi is also included in this finding.

CTB finding	Localisation available	Definition
Chronic or fungal sinusitis	No	Signs that indicate chronic or fungal infection of the sinus i.e. calcification or hyperdensity within the mucosal opacity or thickening of the walls of the sinus.
Chronic subdural haematoma	Yes	Hypodense crescent shaped CSF dense collection extending over the cortical surface of the brain. Includes subdural hygromas.
Cochlear implant	No	Electronic device with electrode implanted into the basal turn of cochlea to treat deafness.
Colloid cyst	Yes	A hyperdense or isodense cyst abutting the anterior roof of the third ventricle.
Colpocephaly	No	Colpocephaly is a descriptive term for a disproportionate prominence of the occipital horns of the lateral ventricles. It can result from a wide range of congenital insults, in particular, callosal agenesis.
Communicating hydrocephalus/NPH	No	Enlargement of the ventricular system involving all ventricles, without evidence of ventricular obstruction.
Corpus callosum agenesis/hypogenesis	No	Complete or partial absence of the corpus callosum due to developmental anomaly.
Cortical laminar necrosis	No	Gyriform hyperdensity, may be calcification or blood products, due to chronic cortical death, usually secondary to hypoxic/ischaemic insult. Will be associated with thinning of the cortex. Often associated with encephalomalacia.
Cortical or leptomeningeal calcification	No	Gyriform calcific density in the cortex, can be secondary to old infarcts or congenital lesions like Sturge Weber or post infectious causes.
Craniotomy/cranioplasty /craniectomy	No	Removal of calvarial bone. Includes replacement of calvarial bone by bone or implant. Also includes burr holes.
Craniotomy extra-axial collection	No	Collection of fluid or haematoma deep to the craniotomy site, commonly seen post craniotomy.
Deep brain stimulation electrodes	No	Electrodes extending through frontal lobes to basal ganglia, subthalamus or brainstem for treating movement disorders such as Parkinson's Disease.
Deep white or grey matter infarct	No	Small old hypodensity in periventricular white matter, lentiform nuclei, caudate, thalami, brainstem > 15mm. Due to old infarct in distribution of the perforating vessels.

CTB finding	Localisation available	Definition
Diffuse hypoxic-ischaemic encephalopathy	No	Generalized swelling of the gyri and loss of sulcal space. Can have loss of grey-white matter differentiation, or reversal of grey and white matter attenuation. Includes metabolic insults like methanol poisoning
Dilated superior ophthalmic vein	Yes	Dilated superior ophthalmic vein of greater than 4mm diameter involving the whole length of the vessel within the orbit. May also be hyperdense due to thrombus.
Disappearing basal ganglia sign	Yes	Obscuration of basal ganglia due to reduced density, in the setting of an acute MCA infarct.
Dural calcification	No	Calcification of the dura, due to chronic haematoma or infection. Does not include physiological calcification of the falx.
Effacement of basal cisterns	No	Obscuration of the basal cisterns e.g. suprasellar cistern or cisterna magna, due to mass effect caused by intra-axial or extra-axial lesions.
Empty sella	No	Pituitary fossa is largely empty of tissue. Often associated with expanded pituitary fossa.
Encephalomalacia	No	Focal loss of brain parenchymal volume due to chronic insult.
Entrapment of lateral ventricle	Yes	Enlargement of a portion of the lateral ventricle due to compression proximally by mass effect. Typically, entrapment occurs in the temporal horn of a lateral ventricle.
Erosion of bone in tympanic cavity	Yes	Erosion of the walls of the tympanic cavity, the ossicles or scutum as seen with cholesteatoma or tumours.
Exophthalmos	Yes	Greater than 23mm protrusion of the anterior surface of the globe beyond the interzygomatic line.
Expanded pituitary fossa	No	Enlargement of the pituitary fossa greater than 17mm in length and 13mm in height. Includes erosion of the dorsum sellae due to expanded sella from long standing raised ICP.
Extracranial herniation	No	Brain herniation external to the inner table of the skull.
Extracranial Ventricular Drain (EVD)	No	Surgically placed drain usually positioned in the anterior horn of a lateral ventricles to reduce intraventricular pressure or surgically placed tubing to measure the intraventricular pressure.

CTB finding	Localisation available	Definition
Extradural haematoma	Yes	Extradural haematoma – biconvex, lens-shaped bleed, often constrained by cranial sutures.
Face and neck haematomas	No	Haematoma in the neck or face which may be due to recent trauma or surgery.
Focal intra-axial calcification	Yes	Foci of calcification within the cerebral hemispheres, brainstem or cerebellum. May be a vascular lesion such as a cavernoma or chronic infection such as cysticercosis.
Foreign body face and neck	Yes	Non-surgical foreign body in the soft tissues of the neck or face. This does not include surgically implanted devices or lines or subcutaneous calcifications.
Foreign body orbit	Yes	Non-surgical foreign body in the orbit. This does not include surgically implanted devices or lines or subcutaneous calcifications.
Foreign body scalp	Yes	Non-surgical foreign body in the soft tissues of the scalp. This does not include surgically implanted devices or lines or subcutaneous calcifications.
Fourth ventricular effacement	No	Effacement, narrowing or compression of fourth ventricle due to mass effect.
Fracture of calvarium	Yes	Acute fracture line through the calvarium, also includes suture diastasis secondary to trauma.
Fracture of skull base	Yes	Fracture involving the base of skull. Includes fractures of the occipital condyles.
Fracture paranasal sinuses/facial bones	Yes	Acute fracture of the facial bones including orbits, paranasal sinuses, nasal bone, maxilla, mandible. Fractures that have surgical fixation, even if recent, come under the definition of 'sino-nasal surgery'.
Generalised calvarial thickening	No	Bone density is increased throughout the calvarium. Includes thickening of calvarium due to Paget's or medication.
Haemorrhagic contusion	Yes	Hyperdense blood within a brain contusion. Common sites include the anterior frontal and temporal lobes. Due to head trauma.

CTB finding	Localisation available	Definition
Haemorrhagic lesion in sella	Yes	<p>Haematoma in the sella and/or suprasellar region. This is usually caused by haemorrhage into a pituitary adenoma, often associated with pituitary apoplexy.</p> <p>Pituitary mass may be evident and may be hyperdense. Fluid-debris levels may also be evident.</p> <p>Also includes haematoma post transsphenoidal surgery.</p>
Hyperdense artery in anterior circulation	Yes	Density consistent with clot in the lumen of the middle or anterior cerebral artery or branches.
Hyperostosis frontalis	No	<p>Benign overgrowth of the inner table of the frontal bone, more common in women over 65 years old.</p> <p>Nodular bony formations on the inner table, protruding greater than 1cm in thickness beyond the adjacent normal component of the calvarium.</p>
Hypopneumatised mastoid	No	<p>Bone is present in the mastoid instead of air cells.</p> <p>The lack of pneumatised mastoid air cells is usually congenital or due to childhood mastoiditis.</p>
Insular ribbon sign	Yes	Hypodensity of insular cortex, obscuring the border with the external capsule, in the setting of an acute MCA infarct.
Intraaxial lesion calcification	Yes	<p>Any partially calcified mass lesion within the cerebrum, cerebellum or brainstem.</p> <p>Also applies to a cyst or mass that has a calcified component or wall.</p>
Intraaxial lesion complex cyst	Yes	<p>Complex cyst within the cerebrum, cerebellum or brainstem, not CSF.</p> <p>May have adjacent oedema.</p>
Intraaxial lesion haemorrhage	Yes	<p>Any mass lesion within the cerebrum, cerebellum or brainstem containing haemorrhage.</p> <p>Any intraaxial lesion can have 'intraaxial lesion haemorrhage' as an additional finding.</p> <p>Does not include haemorrhagic infarct or intraparenchymal haemorrhage with no underlying lesion.</p>
Intraaxial lesion heterogeneous	Yes	Heterogeneous mass lesion within the cerebrum, cerebellum or brainstem with hypodense or hyperdense or isodense components.
Intraaxial lesion hyperdense	Yes	Homogeneous hyperdense cerebral, cerebellar or brainstem mass, e.g. due to lymphoma.

CTB finding	Localisation available	Definition
Intraaxial lesion hypodense	Yes	Homogeneous hypodense mass lesion within the cerebrum, cerebellum or brainstem. The density of the mass is relative to normal brain parenchyma (not the adjacent vasogenic oedema).
Intraaxial lesion isodense	Yes	Cerebral, cerebellar or brainstem mass, homogeneous and isodense relative to the surrounding brain parenchyma. The density of the mass is relative to normal brain parenchyma (not the adjacent vasogenic oedema).
Intra-ocular silicone	Yes	Intra-ocular injection of silicone (hyperdense) for treatment of retinal detachment.
Intra-ventricular haemorrhage	Yes	Acute haemorrhage (hyperdense) within the ventricular system. Causes fluid/fluid levels, usually seen in posterior horns of lateral ventricles. Can be due to trauma, hypertension or haemorrhagic lesions.
Left/Right ventricular effacement	Yes	Effacement, narrowing or compression of lateral ventricle due to mass effect.
Mastoidectomy	Yes	Any type of mastoidectomy or surgery to petrous temporal bones.
Mastoid opacification	No	Partial or complete opacification of the mastoid air cells, typically secondary to fracture, mastoid effusion, or rarely mastoiditis.
Meningioma with hyperostosis of adjacent calvarium	Yes	Meningioma with hyperostosis of adjacent calvarium.
Metallic artefact	No	Streaking artefact, called beam hardening artefact, due to the presence of metallic density object in the field of image acquisition. e.g. braces or external frame.
Midline shift	Yes	Subfalcine herniation or displacement of the medial cerebral hemisphere or displacement of the mid cerebellum laterally by greater than 2mm.
Movement artefact	No	Artefact causing blurring and obscuration of the image due to motion of the patient during the scan.
Mucosal thickening	No	Greater than 5mm thickening of mucosa (over a length of more than 10mm) in the paranasal sinuses. Includes sino-nasal polyposis, mucosal retention cysts and polyps.
Non-aggressive extra-axial mass containing calcification	Yes	Meningioma containing areas of calcification.

CTB finding	Localisation available	Definition
Non-aggressive extra-axial mass without calcification or fat	Yes	Meningioma without aggressive features.
Non-aggressive skin lesion	Yes	Non-aggressive soft tissue lump in the scalp including sebaceous or epidermal cysts.
Obstructive hydrocephalus	No	Enlargement of one or more ventricles due to complete obstruction.
Old lacunar infarct	No	Small old hypodensity in lentiform nuclei, caudate, thalami, brainstem or periventricular white matter greater than 2mm and less than 15mm in diameter.
Opacity in tympanic cavity	Yes	Opacification of the middle ear cavity due to middle ear effusion, haemotympanum, chronic otitis media or cholesteatoma.
Orbital fat stranding	Yes	Ill-defined fat stranding in the orbit. May be due to orbital cellulitis or retro-orbital haemorrhage.
Orbital mass benign	Yes	Well-defined soft tissue mass or cystic lesion in the orbit (intra and extraconal) separate to the extra-ocular muscles. Includes vascular lesions and optic nerve sheath meningiomas.
Orbital mass inflammatory or malignant	Yes	Orbital mass which is ill-defined and may involve one or more extra-ocular muscles in which case it usually involves the myotendinous junction. May have associated fat stranding.
Osteoma	Yes	Homogenous sclerotic benign lesion which can be in paranasal sinuses or skull vault.
Parotid lesion	Yes	Solid or cystic parotid lesions.
Perimesencephalic/aneurysmal subarachnoid haemorrhage	Yes	Hyperdensity in subarachnoid perimesencephalic and basal cisterns, interhemispheric fissure, or sylvian fissures
Petrous bone fracture	Yes	Fracture of the petrous temporal bones. Often longitudinal or transverse.
Pineal mass or complex cyst	Yes	Mass, cystic mass or complex cyst within the pineal region with soft tissue component greater than 1 cm in width and length.
Pneumocephalus	Yes	Subarachnoid, subdural or extradural collection of air density or intraventricular air.
Prominent perivascular spaces	No	Prominent perivascular spaces are CSF density spaces typically found below the basal ganglia at the anterior commissure level.



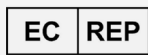





CTB finding	Localisation available	Definition
Prosthetic globe	Yes	Fabricated replacement of the globe in the orbit.
Resection cavity	Yes	Acute/subacute surgical resection cavity following excision of a mass which may contain blood, fluid or gas.
Scalp haematomas	No	Haematoma in the scalp usually due to recent trauma or surgery. Includes post-surgical collection superficial to craniotomy.
Sella or suprasellar cyst, mass or cystic mass	Yes	Cyst, cystic/solid or solid mass in sella or suprasellar region. This includes pituitary tumours, Rathke's cleft cysts, suprasellar tumours and abnormal thickening of the pituitary stalk from inflammatory conditions (hypophysitis).
Simple pineal cyst	Yes	Simple cyst within the pineal region greater than 1 cm in diameter.
Sino-nasal, oral, mandibular and maxillofacial surgery	No	Evidence of previous sino-nasal surgery such as maxillary antrastomies or ethmoidal clearance and fixation of facial bone fractures.
Sinus soft tissue density lesion	No	Soft tissue density lesion in the sinus, secondary to organising haematoma or cancer.
Small vessel ischaemic disease	No	Chronic hypodensity in the white matter, often confluent, typically in the periventricular or deep white matter.
Soft tissue mass in the neck	Yes	Any soft tissue mass in the neck or infratemporal fossa including abscesses/ masses at the fossa of Rosenmuller, oral and nasopharyngeal cavity masses, enlarged (> 1.5cm short axis) or necrotic lymphadenopathy. Includes extra-osseous extension of bony lesions into the soft tissue, soft tissue mass in the face and calcified nodes in the neck.
Striatocapsular slit-like chronic hemorrhage	No	Small old slit-like hypodensity in lentiform nuclei, caudate, thalami, brainstem or periventricular white matter resulting from a previous hypertensive bleed.
Subacute intraparenchymal haemorrhage	Yes	Subacute haematoma (4 to 21 days, usually isodense), in the cerebral hemispheres, including basal ganglia, periventricular white matter, brainstem or cerebellum, not due to cerebral contusion or an underlying lesion.
Subacute subdural haematoma	Yes	Isodense crescent shaped haematoma extending over the cortical surface of the brain.

CTB finding	Localisation available	Definition
Subcutaneous emphysema	No	Air within subcutaneous tissues, usually due to fractured paranasal sinuses, ruptured larynx or trachea, penetrating injury or extension of subcutaneous emphysema from the chest.
Subependymal calcification or nodules	No	Calcification of the subependymal tissues < 1cm. Usually calcified subependymal nodules are associated with tuberous sclerosis. Also includes non-calcified subependymal nodules due to tuberous sclerosis.
Sulcal effacement	No	Effacement, narrowing or compression of sulci due to mass effect.
Temporomandibular joint arthritis	No	Narrowing of the temporomandibular joint space and osteophyte formation or erosions.
Temporomandibular joint dislocation	Yes	Dislocation or subluxation of the temporomandibular joint.
Third ventricular effacement	No	Effacement, narrowing or compression of third ventricle due to mass effect.
Tonsillar herniation	Yes	Downward extension of the cerebellar tonsils through the foramen magnum due to raised intracranial pressure.
Transepandymal oedema	No	Hypodensity along ventricular walls due to increased pressure from hydrocephalus, most commonly seen adjacent to the frontal and occipital horns of the lateral ventricles.
Transphenoidal surgery	No	Surgical resection performed through the sphenoid sinus, typically for resection of sellar or suprasellar lesions.
Uncal herniation	Yes	Downward herniation of the inferior medial temporal lobe through the incisura of the cerebellar tentorium.
Vascular clips	No	Surgical clips placed on vessels within the skull cavity. Includes aneurysmal clips. Does not include craniotomy clips, or other clips outside the cranial vault.
Vasogenic oedema	Yes	Deep white matter hypodensity extending into subcortical white matter.
Ventricular cyst/xanthogranulomatous change	Yes	CSF density cyst within the ventricles > 1cm diameter. This includes choroid plexus lesions like xanthogranulomatous cysts.
Ventricular mass	Yes	Cystic/solid intraventricular mass. Includes choroid plexus lesions such as choroid plexus lipoma.

CTB finding	Localisation available	Definition
Ventriculoperitoneal (VP) Shunt	No	Tubing extending from ventricles to the peritoneal cavity to treat hydrocephalus. Tubing typically passes through the parietal lobe into the body of the lateral ventricle.
Vitreous haemorrhage	Yes	Hyperattenuation, which may be either homogeneous or heterogeneous, in the vitreous chamber.

Symbol glossary

Definitions of symbols that may appear on the Annalise product or in the related documentation are listed below.

Symbol	Information
	CE labelling in accordance with EC directive
	Manufacturer
	European Authorised Representative
	Indicates a warning or caution
	Read the instructions for use
	Medical Device
	Unique Device Identification
	Translation



ANNALISE-AI PTY LTD,
Level 21, 60 Margaret Street,
Sydney, NSW 2000
AUSTRALIA

ABN: 92 635 645 260

ANNALISE-AI UK LTD,
100 New Bridge Street,
London, EC4V 6JA
ENGLAND

Company no: 12804340

support@annalise.ai
www.annalise.ai



OPT-PRM-027 Ver. 0